

Extractions, Implant Placement, and Immediate Loading of Mandibular Implants: A Case Report of a Functional Fixed Prosthesis in 5 Hours

Vicki C. Petropoulos, DMD, MS,* Thomas J. Balshi, DDS,† Stephen F. Balshi, BBE,‡ Glenn J. Wolfinger, DMD§

It is clinically recognized that osseointegrated dental implants, following traditional protocols, provide the dental profession with a predictably successful method of solving problems related to complete and partial edentulism.¹ There are, however, many dental professionals and large patient populations who are reluctant to accept the validity and success this treatment offers.² Dental professionals and patients often think that implant treatment is too costly, too time-consuming, and too painful with long periods of using uncomfortable interim prostheses.² Many patients are under the impression that they will be without teeth for extended lengths of time. This factor has a tremendous psychologic and social impact on patient acceptance of implant treatment.

The profession has sought to reduce the treatment time for dental implant rehabilitation by shortening the healing time using the following approaches: 1) early loading of implants³⁻⁵; 2) immediate loading of implants⁶⁻¹⁰; 3) developing implant surfaces intended to accelerate the osseointegration process^{11,12}; 4) immedi-

The purpose of this report is to present a reliable surgical and prosthodontic protocol for immediate loading of implants, allowing patients to receive a fixed implant-supported prosthesis in a matter of hours. The surgical, prosthodontic, and laboratory steps for this protocol of immediate functionally loading the implants are described for the treatment of a 51-year-old woman who presented with a hopeless mandibular dentition and an edentulous maxillary arch. It is possible to decrease the treatment time in successfully restoring the patient's oral function by means of immediate functional loading of dental implants and immediately placing a

fixed implant-supported prosthesis. Compared with the traditional implant protocols, this protocol of a one-visit approach for patient treatment 1) decreases the number of office visits; 2) decreases the treatment time; 3) reduces the patients' costs; 4) allows the patient to avoid wearing a removable interim prosthesis; and 5) increases the patients' acceptance of treatment while maintaining predictability in treating mandibular edentulism. (Implant Dent 2003;12: 283-290)

Key Words: dental implant, mandible, extraction, immediate loading, customized fixed mandibular conversion prosthesis

ately placing the implants into the tooth extraction sites¹³⁻¹⁷; and 5) developing the Brånemark Novum System (Nobel Biocare, Yorba Linda, CA) for the fabrication of a final, fixed prosthesis.¹⁸ All of these methodologies reflect a desire not only to reduce treatment time, but also to increase patient acceptance.

Unlike traditional osseointegrated implant therapy, which could take 1 to 2 years from the initiation of treatment to completion of the final prosthesis, the "expedited patient care" (Teeth in a Day) protocol¹⁹ reduces treatment time and increases patient acceptance by providing fixed rehabilitation in one treatment visit in a matter of 5 hours. The protocol demonstrated in the following patient treatment report

is based on the successful research for immediate loading of Brånemark implants, which has been published in the dental literature.^{20,21} The results of implant survival following the "expedited patient care" protocol has been equivalent to the survival rates for patients treated with traditional submerged healing times of 3 to 6 months for Brånemark implants in the mandible and maxilla, respectively.²²

CASE REPORTS

Patient History

The patient was a 51-year-old woman who avoided dentistry for many years because of severe anxiety and dental phobia. The patient was taking Ibuprofen analgesics because of

*Assistant Professor of Restorative Dentistry, Department of Restorative Dentistry, University of Pennsylvania School of Dental Medicine, Consultant Prosthodontist Veterans Affairs Medical Center, Philadelphia, Pennsylvania.

†Prosthodontics Intermedica, Institute for Facial Esthetics, Washington, Pennsylvania.

‡Postgraduate student, Drexel University, School of Biomedical Engineering and Science, Philadelphia, Pennsylvania.

§Prosthodontics Intermedica, Institute for Facial Esthetics, Fort Washington, Pennsylvania; Staff Prosthodontist Veterans Affairs Medical Center, Philadelphia, Pennsylvania; and Lecturer, Department of Prosthodontics, Columbia University School of Dental and Oral Surgery, New York, New York.

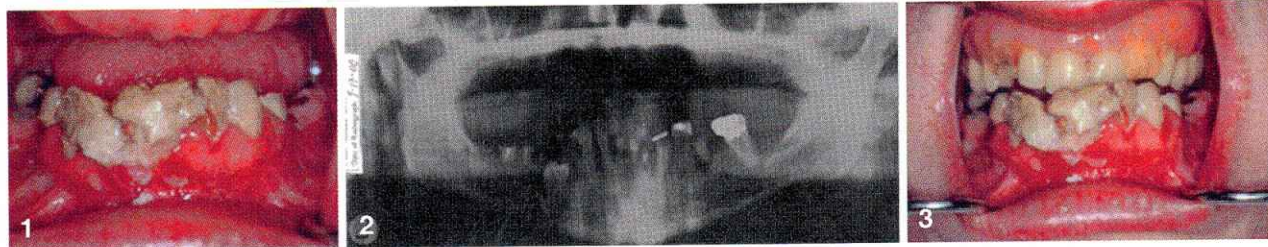

Fig. 1. Intraoral view of mandibular-deteriorated dentition.

Fig. 2. Preoperative panoramic radiograph shows advanced periodontal disease, caries, periapical abscesses, and an impacted bicuspid.

Fig. 3. Intraoral view shows the occlusion of the remaining hopeless teeth with an extremely worn and deteriorated maxillary denture.

long-standing dental pain. With the exception of an allergy to penicillin and frequent migraine headaches, her medical history was noncontributory. The patient did admit to smoking cigarettes at the rate of one pack per week.

The patient's dental history consisted of some childhood restorative care and many years of multiple extractions leading to an edentulous maxilla and a partially dentate mandible. The 15-year-old maxillary denture had multiple cracks and missing teeth. Her mandibular dentition included an impacted bicuspid, fractured roots, and periodontally hopeless teeth (Fig. 1). Her last dental treatment had been a 10 years previously, and it significantly contributed to her high anxiety toward further dental care.

Comprehensive clinical and radiographic evaluations were performed. Panoramic (Fig. 2), lateral cephalometric, and periapical radiographs were obtained. The clinical evaluation revealed an edentulous maxillary arch, which had been restored with a removable complete denture that had completely deteriorated (Fig. 3). Many of the mandibular natural teeth were held in position using cyanoacrylate (Superglue; 3M, Minneapolis, MN) that the patient self-administered for several years because of her fear of further dental treatment (Figs. 1 and 3). The patient's chief complaint was that "my teeth are falling out of my gums and I do not want to walk around toothless." The patient expressed her concern that she did not want to be without any teeth even for a temporary period of time. An impacted left bicuspid was surrounded by fractured roots, teeth with advanced caries, and periodontal disease. Multiple periapical abscesses were also present. The re-

maining mandibular dentition was diagnosed as restoratively hopeless as a result of advanced periodontal disease.

After a general discussion about the patient's chief complaints, desires, concerns, and expectations, the patient was presented with various options. A treatment plan was formulated to include immediate placement of eight Brånemark System dental implants (Nobel Biocare) in the mandibular arch and to immediately load them with an implant-supported fixed conversion prosthesis. The patient declined having implants placed in the maxillary arch and was satisfied with the treatment plan of a new removable complete denture to restore her maxilla. Despite her previous negative dental experiences and fears of treatment, the patient wanted to begin treatment immediately.

Alginate impressions were made of the mandible and maxilla. Diagnostic casts were made and articulated at the established vertical dimension of occlusion to provide the technical staff with the necessary information for the construction of an immediate conventional maxillary complete denture and an all-acrylic resin conversion fixed implant-supported prosthesis, which would be immediately placed in the mandibular arch the day of the implant placement.

Dental Laboratory Procedures

The initial dental laboratory procedures occurred during the time required to review the consent for treatment forms and the administration of local anesthesia. After articulation of the diagnostic casts, a set of prefabricated dentures was selected to comply with the patient's facial appearance and arch form (Fig. 4A). The dental laboratory technicians loosely retrofit-

ted the prefabricated maxillary and mandibular dentures to the diagnostic casts while the surgical treatment began. Immediate complete removable dentures were fabricated (Fig. 4B) using the edentulous ridges to maintain the vertical dimension of occlusion. A wire was placed on the labial surface of the mandibular denture using orthodontic resin (Lang, Wheeling, IL).

Surgical Treatment

The remaining periodontally hopeless teeth and the impacted left bicuspid were removed (nos. 19–29 and 31) after administering local anesthesia consisting of bilateral blocks and infiltration using 4 carpules of Marcaine (Cook-Waite, Abbott Laboratories, North Chicago, IL) 1:200,000, and 2 carpules of Lignospan (Septodont, Inc., New Castle, DE) 1:50,000. The extraction sockets were thoroughly debrided of all soft tissue and pathology and irrigated with a solution of 500 mg tetracycline powder to 100 cc sterile saline. Biopsies were performed in areas of nos. 19, 23, and 29 and sent out to an oral pathology laboratory for evaluation. Enough alveoplasty was performed to level and smooth the bone in the area of the anterior extraction sites as well as to accommodate the height of the components and prosthetic replacement materials. A crestal incision was made with dissection and flap elevation to identify the mental foramina and other deep anatomic landmarks.

Using the traditional osteotomy protocol for the placement of Brånemark implants, 8 TiUnite implants (Nobel Biocare) were placed in the mandibular arch: 6 3.75 × 8-mm implants between the mental foramina and 2 4.0 × 0-mm implants, one placed distally in each first molar area.

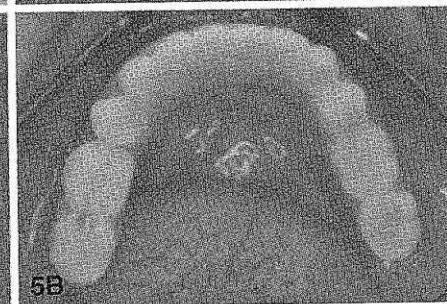
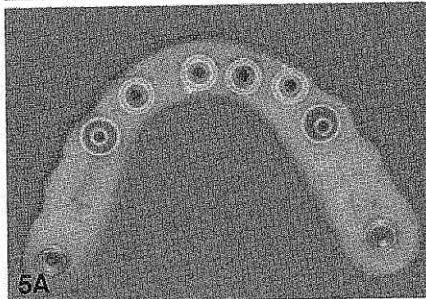
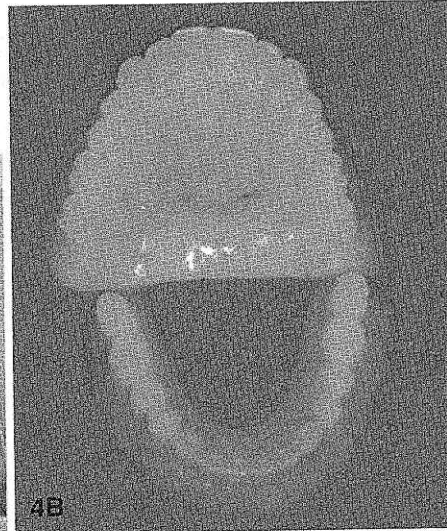
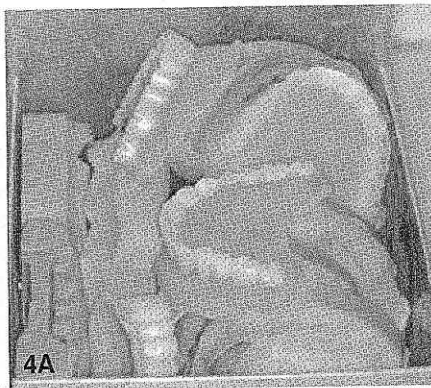


Fig. 4. (A) Prefabricated dentures with different arch forms and teeth moulds can be selected for the patient's immediate prostheses. **(B)** Maxillary immediate complete denture and immediate mandibular implant-supported fixed prosthesis.

Fig. 5. (A) The undersurface of the immediate mandibular implant-supported prosthesis showing the prosthetic-fastening components. **(B)** Occlusal view of the immediate mandibular implant-supported prosthesis.

Minimal bone tapping was used to ensure maximal stability of the implants.

Prosthodontic Procedure: Abutment Connection and The Fixed Conversion Prosthesis

After implant placement, appropriate abutments were selected and connected to the implants with torque-controlled tightening to the recommended 20 Ncm. The junction of the implant and abutments were all visible and were universally 1 mm supraosseous. Autogenous bone grafting was done around all the implants and around all the extraction sites.

Customized prosthetic cylinders (fabricated from stainless steel, screw-retained Brånemark impression copings) were placed onto the abutments and secured with customized-length guide pins that permitted the mandible to be closed in centric relation without the components interfering with the occlusion. transfer ink (Dr. Thomp-

son's Ink Stick; Great Plains Dental Products, Kingman, KS) was then applied to the top of the guide pins and a rubber dam (Hygenic; Coltene, Mahwah, NJ) was positioned over them to record the position of the implants. A punch was used to create a hole in the rubber dam at each site marked by the transfer ink. The rubber dam was then gently eased over each guide pin and impression coping, taking care to avoid creating folds in the rubber dam. The immediate maxillary denture was inserted. After this, the mandibular immediate denture was tried-in. The denture was relieved to allow for seating without contact with the implant components. Once the denture was relieved and fitted, a 50-mL syringe loaded with Jet Acrylic (Lang) was injected to coat all the prosthetic components (Fig. 5A). Additional acrylic resin was placed on the internal surface of the modified immediate man-

dibular complete denture connecting it to the prosthetic cylinders using the conversion prosthesis protocol.^{23,24} The denture-bearing areas of this prosthesis were kept free of contact with the acrylic to maintain the proper vertical dimension of occlusion.

The mandibular conversion prosthesis was placed in the proper interocclusal position in centric relation, and the patient was instructed not to move for approximately 4 minutes. As the acrylic polymerized, the rubber dam insulated the hard and soft tissues from the released heat. The rubber dam also ensured that no undercuts between the abutments were engaged when the acrylic resin polymerized. The mandibular conversion prosthesis was removed after the acrylic set and was refined and polished in the laboratory (Fig. 5B).

While the prosthesis was being refined in the dental laboratory, the soft tissue was approximated, obtaining secure adaptations around the titanium abutments using 4.0 Vicryl sutures (Johnson & Johnson, Somerville, NJ; Fig. 6A). Postoperative panoramic (Fig. 6B) and cephalometric radiographs were taken to evaluate the positions of the implants.

The completed prosthesis was attached to the abutments with gold prosthetic screws, and the occlusal relationship was again reevaluated. The screw access holes were sealed with a cotton pellet and Fermit (Ivoclar, Amherst, NY). The completed prosthesis was delivered to the patient within 1 hour after implant placement (Fig. 7A). The new maxillary denture was relined for maximum stability and delivered to the patient's satisfaction.

Postsurgical Patient Management

The entire treatment process for the immediate placement of implants and immediately functionally loading them with a fixed implant-supported conversion prosthesis took 5 hours from the time the patient first entered the office. Postsurgical patient management included instructions to apply a minimum of 48 hours, and preferably 72 hours, of cold therapy to minimize swelling in conjunction with the standard protocol of medications. These included: Decadron (20 tablets of .75 mg; for the first 2 days 1 tablet

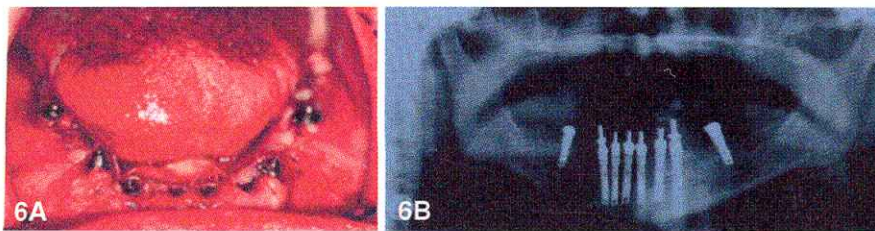


Fig. 6. (A) Intraoral view of the titanium abutments on the mandibular implants immediately after surgery. (B) Panoramic radiograph after tooth extractions and implant placement showing Brånemark implants supporting the mandibular implant-supported conversion fixed prosthesis.

was taken 4 times per day, for the next 2 days 1 tablet was taken 3 times per day, for the next 2 days 1 tablet was taken 2 times per day, for the next 2 days 1 tablet was taken once per day), oral rinse of chlorhexidine (Peridex; Zila Pharmaceuticals, Phoenix, AZ), erythromycin (30 tablets of 333 mg; 1 tablet was taken 3 times per day until finished), Vicoprofen (30 tablets; 1 tablet every 4–6 hours as needed), and Motrin (40 tablets of 600 mg; 1 tablet every 4–6 hours as needed). The patient was also instructed to avoid difficult-to-chew foods and maintain strictly a soft diet for 8 weeks immediately after this expedited treatment. At the 24-hour follow up, the patient reported being totally pain-free, comfortable, and very enthusiastic about her new smile. Suture removal was performed 10 days from the date of her surgery.

Final Prosthesis

After 2 months, the patient presented for fabrication of the final prostheses. An interocclusal registration was taken using Regisil (Dentsply, York, PA). The secondary impression was made using the existing mandibular fixed-conversion prosthesis as an impression stent. Heavy-body Reprosil (Dentsply) impression material was

syringed beneath the all-acrylic mandibular implant and a pick-up impression was made. A master cast was created by placing abutment analogs to the modified impression copings within the acrylic prosthesis. Using the immediate-loaded acrylic conversion prosthesis as an impression stent has shown to create an exceptionally accurate master cast. A wash impression was made inside the maxillary complete denture preserving the proper vertical dimension of occlusion and poured in stone. The interocclusal registration and the provisional restorations were used to articulate the maxillary edentulous cast against the mandibular master cast. The laboratory then began fabricating the final metal-reinforced mandibular implant prosthesis and the final maxillary complete denture.

The patient was seen 1 week later to verify the preliminary tooth setup in wax. The functional and esthetic assessments were determined as well as verification of the recorded vertical dimension of occlusion.

The final metal reinforced tissue-integrated prosthesis and the maxillary complete denture was delivered to the patient within 3 months subsequent to the implant surgery. The occlusion and articulation were checked and the

screw access holes were sealed using cotton and Fermit (Ivoclar; Fig. 7B). The patient was extremely satisfied with the function and the appearance of her new smile (Fig. 8A, B).

Follow-up Visits

On the 6-month and 1-year follow-up visits, the patient reported that her migraine headaches subsided. This result is commonly experienced with restoration of an appropriate occlusal vertical dimension. The patient has been functioning well with the final prostheses and was very pleased.

DISCUSSION

The concept of immediate loading of implants using a fixed-conversion prosthesis is based on research of immediate functional loading of Brånemark implants that has been published in the dental literature.^{25,26} The protocol for immediate placement of implants and immediate loading with a customized implant-supported nonremovable prosthesis in 5 hours has been explained. A patient becomes a candidate for immediate loading of their dental implants after assessing their medical and dental history, and their clinical and radiographic appearance, establishing a clear understanding of the patient's needs and desires. The ability of the patient to withstand a minor surgical procedure as well as availability of good bone quality are important criteria. The bone quality has to be good enough to provide primary stability for the implant.

The transitional removable prosthesis is a frequent barrier to patient acceptance of implant treatment.²⁷ Edentulous patients treated with implants can wear an interim, removable, soft-lined complete denture during the healing period. To further protect the implants from premature loading, some clinicians recommend not wearing a denture at all, or at least not during the initial healing phase. The psychologic effects of being without a denture could preclude some patients from seeking implant treatment, and the transition from the natural dentition to edentulism could be difficult. Using this "expedited patient care" treatment (Teeth in a Day) protocol, these problems are overcome because

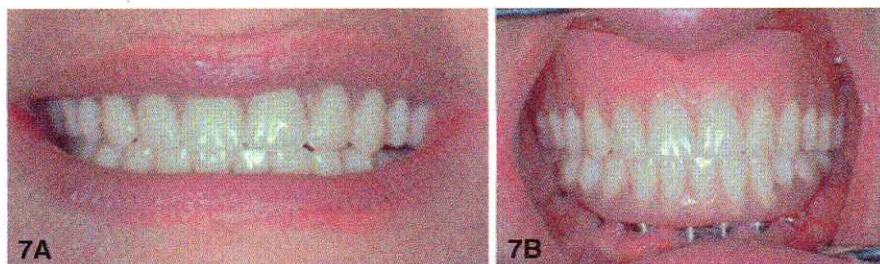


Fig. 7. (A) Postoperative esthetics of patient with fixed implant supported prosthesis 5 hours later. (B) Intraoral frontal view of the final implant-supported mandibular prosthesis.

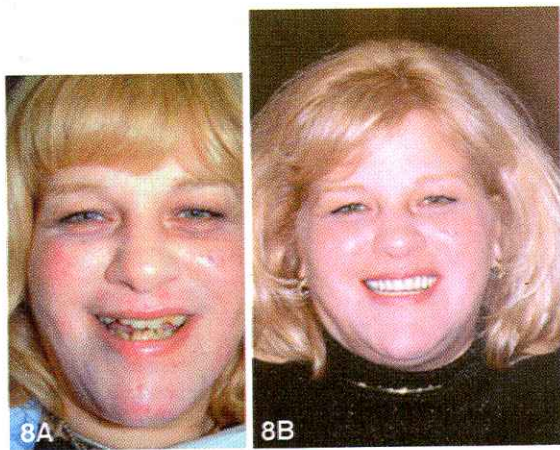

Fig. 8. (A) Preoperative full face condition before the procedure. **(B)** Postoperative esthetics after completion of treatment.

the customized fixed-conversion prosthesis is supported by the titanium fixtures the day of surgery. This immediate implant-supported prosthesis has several functions: 1) it acts as a blueprint for the final prosthesis; 2) it helps to select proper abutments for ideal esthetics; 3) it allows testing of the phonetics and esthetics; 4) it allows for the functional loading during the healing period of osseointegration; 5) it has a splinting effect of locking the implants into place as healing of the alveolar bone occurs; and 6) it creates an accurate master cast by indexing the position of the implants to which bone healing will occur.

Indications for this type of protocol are patients who have enough quantity and quality of alveolar bone to ensure initial stability and success for the immediately loaded implants. They must also be compliant in following all postsurgical instructions, and limit the functional forces during the healing period for osseointegration by maintaining a soft diet for at least the first 2 months after the surgery. When these conditions are met, the results are excellent.²⁸

CONCLUSIONS

The customized protocol outlined in this case report (Teeth in a Day) was developed to fill a special need in dental care. This method of implant prosthodontic rehabilitation provides patients with enormous instant gratification, and can be accomplished using either local anesthesia or general anesthesia for patients having extreme

dental anxiety. Stability, function, and esthetics are instantly gratifying for the patient. The significant differences in postoperative comfort are of great interest. When compared with traditional stage one implant surgery, patients undergoing the "expedited patient care" protocol report having far less discomfort and require fewer postoperative analgesic medications.

Some precautions in case selection include patients with severe parafunctional habits, patients with bone quality that does not allow for primary implant stability, and noncompliant patients who do not follow the postoperative instructions of maintaining a soft diet during the primary healing period.

The evolution to this current approach of extraction, immediate implant placement, and immediate loading with an implant-supported fixed prosthesis relies heavily on the expert prosthetic abilities of the prosthodontist, the professional staff, and the dental laboratory technicians. The cooperative efforts of all team members are essential with this protocol.

ACKNOWLEDGMENTS

The authors gratefully acknowledge the contribution of the Dental Implant Team at Prosthodontics Intermedica, especially James Williams, CDT, Antoinette Robinson, and Robert Winkleman, CDT, MDT, President of Fort Washington Dental Lab, Inc., and also Ruth Cuellar, BS.

DISCLOSURE

The authors claim to have no financial interest in any company or product mentioned in this article.

REFERENCES

1. Adell R, Lekholm U, Rockler B, et al. A 15-year study of osseointegrated implants in the treatment of the edentulous jaw. *Int J Oral Surg*. 1981;10:387-416.
2. Wagenberg BD, Ginsburg TR. Immediate implant placement on removal of the natural tooth: retrospective analysis of 1081 implants. *Compendium*. 2001;22:399-409.
3. Ericsson I, Randow K, Glantz P-O, et al. Clinical and radiographic features of submerged and nonsubmerged titanium implants. *Clin Oral Implants Res*. 1994;5:185-189.
4. Henry P, Rosenberg I. Single-stage surgery for rehabilitation of the edentulous mandible: preliminary results. *Pract Periodont Aesthet Dent*. 1994;6:15-22.
5. Piattelli A, Trisi P, Romasco N, et al. Histological analysis of a screw implant retrieved from man: influence of early loading and primary stability. *J Oral Implantol*. 1993;19:303-306.
6. Schnitman PA, Wohrle PS, Rubenstein JE. Immediate fixed interim prostheses supported by two-stage threaded implants: methodology and results. *J Oral Implantol*. 1990;16:96-105.
7. Wohrle PS, Schnitman PA, Da Silva JD, et al. Brånemark implants placed into immediate function: 5-year results. *J Oral Implantol*. 1992;18:282.
8. Ericsson I, Nilson H, Nilner K. Immediate functional loading of Brånemark single tooth implants. A five year clinical follow-up study. *Applied Osseoint Res*. 2001;2:12-16.
9. Tarnow DP, Emtiaz SE, Classi A. Immediate loading of threaded implants at stage 1 surgery in edentulous arches: ten consecutive case reports with 1-to 5-year data. *Int J Oral Maxillofac Implants*. 1997;12:319-324.
10. Wohrle PS. Single tooth replacement in the aesthetic zone with immediate provisionalization: fourteen consecutive case reports. *Pract Periodontics Aesthet Dent*. 1998;9:1107-1114.
11. Babbush CA, Kent J, Misiak D. Titanium plasma-sprayed (TPS) screw implants for the reconstruction of the edentulous mandible. *J Oral Maxillofac Surg*. 1986;44:274-282.
12. Schroeder A, Maeglin B, Sutter F. Das ITI-hohlzylinderimplantat typ F zur prothesenretention beim zahnlosen kiefer. *Schweizerische Monatschrift fur Zahnheilkunde*. 1983;93:720-733.
13. Rosenquist B, Grenthe B. Immediate placement of implants into extraction

sockets: implant survival. *Int J Oral Maxillofac Implants.* 1996;11:205-209.

14. Cosci F, Cosci B. A 7-year retrospective study of 423 immediate implants. *Compend Contin Educ Dent.* 1997;18:940-942.

15. Schwartz-Arad D, Chaushu G. Placement of implants into fresh extraction sites 4 to 7 years retrospective evaluation of 95 immediate implants. *J Periodontol.* 1997;68:1110-1116.

16. Schwartz-Arad D, Grossman Y, Chaushu G. The clinical effectiveness of implants placed immediately into fresh extraction sites of molar teeth. *J Periodontol.* 2000;71:839-844.

17. Barzilay I, Graser GN, Iranpour B, et al. Immediate implantation of a pure titanium implant into an extraction socket: report of a pilot procedure. *Int J Oral Maxillofac Implants.* 1991;6:277-284.

18. Brånemark PI, Engstrand P, Öhrnell LO, et al. Brånemark Novum: a new treatment concept for rehabilitation of the edentulous mandible. Preliminary results from a prospective clinical follow-up study. *Clin Implant Dent Relat Res.* 1999;1:2-16.

19. Balshi TJ, Wolfinger GJ. Immediate placement and implant loading for expe-

ditioned patient care: a case report. *Int J Oral Maxillofac Implants.* 2002;17:587-592.

20. Balshi TJ, Wolfinger GJ. Immediate loading of Brånemark implants in edentulous mandible: a preliminary report. *Implant Dentistry.* 1997;6:83-88.

21. Cooper LF, Rahman A, Moriarty J, et al. Immediate mandibular rehabilitation with endosseous implants: Simultaneous extraction, implant placement and loading. *Int J Oral Maxillofac Implants.* 2002;17:517-525.

22. Wolfinger GJ, Balshi TJ, Rangert B. Immediate functional loading of Brånemark system implants in edentulous mandibles: clinical report of the results from developmental and simplified protocols. *Int J Oral Maxillofac Implants.* 2003;18:250-257.

23. Balshi TJ. The Biotes Conversion prosthesis: a provisional fixed prosthesis supported by osseointegrated titanium fixtures for restoration of the edentulous jaw. *Quintessence Int.* 1985;16:667-677.

24. Balshi TJ, Wolfinger GJ. Conversion prosthesis: a transitional fixed implant-supported prosthesis for an edentulous arch—a technical note. *Int J Oral Maxillofac Implants.* 1996;11:106-111.

25. Balshi TJ, Wolfinger GJ. A new

protocol for immediate functional loading of dental implants. *Dent Today.* 2001;20:60-65.

26. Szmuckler-Moncler S, Platelli A, Favero GA, et al. Considerations preliminary to the application of early and immediate loading protocols in dental implantology. *Clin Oral Implants Res.* 2000;11:12-25.

27. Blomberg S. Psychological response. In: Brånemark P-I, Zarb GA, Albrektsson T, eds. *Tissue-Integrated Prosthesis.* Chicago: Quintessence; 1985:165-174.

28. Balshi TJ, Wolfinger GJ. Immediate implant loading: a new protocol for esthetic restorations. *Contemporary Esthet and Rest Prac.* 2002;6:40-44.

Reprint requests and correspondence to:

Vicki C. Petropoulos, DMD, MS
University of Pennsylvania School of Dental Medicine
4001 Spruce Street
Department of Restorative Dentistry
Philadelphia, PA 19104-6003
Phone: (215) 898-8980
Fax: (215) 573-9606
E-mail: VPetropoulos@aol.com



Abstract Translations [German, Spanish, Portugese, Japanese]

AUTOR(EN): Vicki C. Petropoulos, D.M.D., M.S.*, Thomas J. Balshi, DDS**, Stephen F. Balshi, BBE†, Glenn J. Wolfinger, DMD‡. *stellvertretender Professor für wiederherstellende Zahnheilkunde, Abteilung Wiederherstellende Zahnheilkunde, Universität von Pennsylvania, zahnmedizinische Fakultät; Facharzt für Prothetik, VA Medizinisches Zentrum, Philadelphia, Pennsylvania. **Prothodontics Intermedia, Institut für Gesichtsästhetik, Washington, Pennsylvania. †Student des Postgraduiertenkollegs, Drexel Universität, Fakultät Biomedizinische und-wissenschaft, Philadelphia, Pennsylvania. ‡Prothodontics Intermedia, Institut für Gesichtsästhetik, Fort Washington, Pennsylvania; Prothetiker des VA Medizinischen Zentrums, Philadelphia, Pennsylvania; Dozent, Abteilung für Zahnersatzkunde, Columbia Universität, Fakultät Kiefer- und Gesichtschirurgie, New York, New York. Schriftverkehr: Vicki C. Petropoulos, DMD, MS, Universität Pennsylvania University of Pennsylvania, zahnmedizinische Fakultät (School of Dental Medicine), 4001 Spruce Street, Abteilung für wiederherstellende Zahnheilkunde (Department of Restorative Dentistry), Philadelphia, PA 19104-6003. Telefon: (215) 898-8980, Fax: (215) 573-9606. eMail: VPetropoulos@aol.com

AUTOR(ES): Vicki C. Petropoulos, D.M.D., M.S.*, Thomas J. Balshi, DDS**, Stephen F.

Extraktion, Implantateinpflanzung und unmittelbare Belastung bei Implantaten im Unterkiefer: eine Fallstudie einer innerhalb von 5 Stunden gesetzten festen Funktionalprothese

ZUSAMMENFASSUNG: ZIELSETZUNG: Die vorliegende Studie möchte in überzeugender Weise durch Demonstration eines chirurgischen sowie prothetischen Behandlungsansatzes bei unmittelbarer Belastung der eingepflanzten Implantate darlegen, dass es möglich ist, Patienten innerhalb weniger Stunden mit einer festen implantatgestützten Prothese aus der Erstbehandlung zu entlassen. MATERIALIEN UND METHODEN: Die Beschreibung der chirurgischen, prothetischen und labortechnischen Behandlungsschritte für diesen Implantatbehandlungsansatz mit sofortiger Belastung erfolgt auf Basis des Falls einer 51 Jahre alten Frau mit extrem schlechten Gebissstatus im Unterkiefer und Zahnlosigkeit im Oberkieferbogen. ERGEBNISSE: Die erforderliche Behandlungszeit zur erfolgreichen Wiederherstellung der Gebissfunktionalität kann erheblich verkürzt werden, nimmt man eine unmittelbare Belastung der Zahnimplantate mit sofortigem Einsatz der festen implantatgestützten Prothese vor. SCHLUSSFOLGERUNG: Im Vergleich zu den normalen Verfahrensweisen bei Zahnimplantierung zeichnet sich dieser Behandlungsansatz durch seine nur einmalig erforderliche Behandlungsdauer aus: a) die Anzahl der Behandlungstermine wird reduziert, b) die Behandlungszeit wird verkürzt, c) die vom Patienten zu tragenden Kosten werden minimiert, d) dem Patienten wird das Tragen eines Protheseprovisoriums erspart und e) die Behandlungstoleranz beim Patienten wird wesentlich erhöht, während gleichzeitig die gute Behandlungsqualität bei Zahnlosigkeit im Unterkiefer gewahrt bleibt.

SCHLÜSSELWÖRTER: Zahnimplantat, Unterkiefer, Extraktion, unmittelbare Belastung, angepasste feste Konversionsprothetik im Unterkiefer

Balshi, BBE***, Glenn J. Wolfinger, DMD****. *Profesor Asistente de Odontología de Restauración, Departamento de Odontología de Restauración, Facultad de Medicina Dental de la Universidad de Pennsylvania; Prosthodontista Consultor del Centro Médico de la Administración de Veteranos, Philadelphia, Pennsylvania. **Prosthodontics Intermedica, Instituto de Estética Facial, Washington, Pennsylvania. ***Estudiante de Posgrado, Drexel University, Facultad de Ingeniería y Ciencias Biomédicas, Philadelphia, Pennsylvania. ****Prosthodontics Intermedica, Instituto de Estética Facial, Washington, Pennsylvania; Prosthodontista, Centro Médico de la Administración de Veteranos, Philadelphia, Pennsylvania; Disertante, Departamento de Prosthodontia, Facultad de Cirugía Oral y Dental de Columbia University, Nueva York, NY. Correspondencia a: Vicki C. Petropoulos, DMD, MS, University of Pennsylvania School of Dental Medicine, 4001 Spruce Street, Department of Restorative Dentistry, Philadelphia, PA 19104-6003. Teléfono: (215) 898-8980, Fax: (215) 573-9606

AUTOR(ES): Vicki C. Petropoulos, D.M.D., M.S.*. Thomas J. Balshi, DDS**. Stephen F. Balshi, BBL***. Glenn J. Wolfinger, DMD****. *Professor Assistente de Odontologia Restaurativa, Depto de Odontologia Restaurativa, Universidade da Pensilvânia-Faculdade de Odontologia, Consultor Prosthodontista Centro Médico VA, Filadélfia, Pensilvânia. ** "Prosthodontics Intermedica", Instituto para Estética Facial, Washington, Pensilvânia. *** Aluno da Pós Graduação da Universidade Drexel, Faculdade de Engenharia e Ciências Biomédicas, Filadélfia, Pensilvânia. **** "Prosthodontics Intermedica", Instituto para Estética Facial, Fort Washington, Pensilvânia: Equipe Prosthodontista Centro Médico VA, Filadélfia, Pensilvânia: Palestrante, Departamento de Prosthodontia, Universidade de Columbia-Faculdade de Odontologia e Cirurgia Odontológica, Nova Iorque, Nova Iorque. Correspondência a: Vicki C. Petropoulos, DMD,MS, University of Pennsylvania School of Dental Medicine, 4001 Spruce Street, Department of Restorative Dentistry, Philadelphia, PA 19104-6003. Telefone: (215) 898-8980 Fax: (215) 573-9606 email: VPetropoulos@aol.com

Correo electrónico: VPetropoulos@aol.com

Extracciones, colocación de implantes y carga inmediata de implantes mandibulares: Un informe de caso de una prótesis funcional fija en 5 horas

ABSTRACTO: PROPÓSITO: El propósito de este informe es presentar un protocolo quirúrgico y prosthodóntico confiable para la carga inmediata de implantes permitiendo a los pacientes recibir una prótesis apoyada en implantes fijos en una cuestión de horas. **MATERIALES Y MÉTODOS:** Los pasos quirúrgicos, prosthodónticos y de laboratorio para este protocolo de carga funcional inmediata de los implantes se describen para el tratamiento de una mujer de 51 años que presentó una dentadura mandibular sin esperanzas y un arco maxilar edentuloso. **RESULTADOS:** Es posible reducir el tiempo de tratamiento en la restauración exitosa de la función oral del paciente, a través de una carga funcional inmediata de implantes dentales y la colocación inmediata de una prótesis fija apoyada con implantes. **CONCLUSIÓN:** Comparado con los protocolos tradicionales de implantes, este protocolo es un método de 1 visita para el tratamiento del paciente: a) reduce el número de visitas al consultorio; b) reduce el tiempo de tratamiento; c) reduce el costo para el paciente; d) permite que el paciente evite el uso de una prótesis interina removible; y e) aumenta la aceptación del tratamiento del paciente mientras mantiene la previsibilidad en el tratamiento del edentulismo mandibular.

PALABRAS CLAVES: Implante dental, mandíbula, extracción, carga inmediata, prótesis de conversión fija mandibular personalizada

Extracões, Colocação de Implante e Carga Imediata de Implantes Mandibulares: Relatório de Caso de uma Prótese Funcional Fixada em 5 horas.

SUMÁRIO: PROPÓSITO: O propósito deste relatório é apresentar um protocolo cirúrgico e prosthodóntico confiável do preenchimento imediato funcional de implantes que permita aos pacientes receber próteses fixas apoiadas em implantes em uma questão de horas. **MATERIAIS E MÉTODOS:** Os passos cirúrgicos, prosthodónticos e laboratoriais para este protocolo para o preenchimento imediato funcional dos implantes são descritos no tratamento de uma mulher de 51 anos de idade que se apresentou com uma dentição mandibular sem esperança e um arco maxilar edentado. **RESULTADOS:** É possível diminuir o tempo de tratamento na restauração bem sucedida da função oral do paciente, pelo preenchimento funcional imediato de implantes dentários e a colocação imediata de próteses fixas apoiadas em implantes. **CONCLUSÃO:** Comparado aos protocolos de implante tradicionais, este protocolo de enfoque de 1 visita para o tratamento do paciente a) diminui o número de visitas ao consultório; b) diminui o tempo de tratamento; c) reduz os custos do paciente; d) permite ao paciente não usar próteses removíveis no ínterim; e) aumenta a aceitação do paciente ao tratamento enquanto se mantém a predicabilidade no tratamento de edentulismo mandibular.

PALAVRAS-CHAVE: Implante Dentário, mandíbula, extração, preenchimento imediato, próteses de conversão personalizadas fixas mandibulares